

Effect of Dichlorvos on the fertility of adult male albino rats

Ethelbert Uchechukwu Ezeji¹, Oluchi Dominica Ogueri¹, Angela Chika Udebuani¹, Josephath N. Okereke¹, Kalu O. Obasi²

¹ Department of Biotechnology, Federal University of Technology, P.M.B. 1526, Owerri Nigeria

² Department of Biological Science, Federal University of Technology, P.M.B. 1526, Owerri Nigeria

ucheezeji@yahoo.com

Abstract: Continuous use of pesticides could have adverse effects on the reproductive functions of humans and non-target organisms. This study was carried out to examine the effect of dichlorvos on the reproductive parameters of adult male albino rats. Twenty (20) adult male Wistar albino rats weighing between 130 – 225g were divided into 4 groups of 5 animals each. Three groups were given water contaminated with 0.01, 0.03 and 0.05% dichlorvos (DDVP) respectively. The control group was given distilled water without dichlorvos. All the animals were maintained on commercial animal feed (growers mash) throughout the period of the experiment which lasted for 28 days. There were significant reductions ($p < 0.05$) in testosterone levels in rats exposed to dichlorvos. Testicular weight (testis and epididymis) and sperm count were significantly lowered in rats exposed to dichlorvos. Histological examination of the testes revealed levels of distortions in the cells of the seminiferous tubules as well as hypertrophy of the spermatogonia cells. These results show that dichlorvos has adverse effects in the reproductive functions of male albino rats.

[Ezeji EU, Ogueri DO, Udebuani AC, Okereke JN, Obasi, KO. Effect of dichlorvos on the fertility of male albino rats. *Nat Sci* 2015;13(12):1-5]. (ISSN: 1545-0740). <http://www.sciencepub.net/nature>. 1. doi:[10.7537/marsnsj131215.01](https://doi.org/10.7537/marsnsj131215.01).

Keywords: Dichlorvos, fertility, testis, testosterone, albino rats

1. Introduction

The use of pesticides has become a regular phenomenon in both agriculture and general household needs. Continuous use of pesticides is a serious health concern due to their adverse environmental effects (Bloomquist, 1993). Organophosphate insecticides represent one group of pesticides that is widely used and has been shown to have toxic effects in human and animals (De-Bleecker et al., 1993; Eskenazi et al., 1999). Dichlorvos is a widely used organophosphate pesticide applied in the control household pests, in public health, protecting stored product from insects and control of parasites in livestock. Like other organophosphate pesticides, dichlorvos acts by blocking of acetyl cholinesterase – an enzyme which decomposes acetylcholine. The World Health Organization has classified dichlorvos as a highly hazardous and toxic compound (WHO, 1992).

There is an increased concern that exposure to pesticides may adversely affect the reproductive system of humans and other non-target organisms. It has been reported that exposure to agricultural pesticides may affect male fertility (Taylor et al., 2010). Pesticides can damage the male reproductive system in a number of ways: They may damage the sperm cells, alter DNA structure causing gene mutation that may result in birth defects or an inability to conceive or may cause epigenetic effects – change in the way genes are expressed (Collata,

2013). Studies by Bretveld et al. (2007) showed that pesticides may directly damage spermatozoa, alter sertoli cell or leydig cell function or disrupt the endocrine function in any stage of hormonal regulation.

This study was carried out to examine the effect of dichlorvos on reproductive parameters of adult male albino rats.

2. Material and Methods

The insecticide, dichlorvos (DDVP) used in this experiment was purchased from an Agro-chemical shop in Owerri, Imo State, Nigeria. Twenty (20) adult male wistar albino rats weighing between 130 – 225g were obtained from the Department of Veterinary Medicine, University of Nigeria, Nsukka. The animals were housed in plastic cages, fed a standard laboratory diet and water ad libitum, exposed to a 12 h light/dark cycle, and maintained at a laboratory temperature of $20 \pm 2^\circ\text{C}$. The animals were allowed to acclimatize for 10 days before beginning the experiments. All rats were handled in accordance with the standard guide for the care and use of laboratory animals. The rats were divided into 4 groups of 5 animals each. Three groups were given water contaminated with 0.01, 0.03 and 0.05% dichlorvos (DDVP) respectively. The control group was given distilled water without dichlorvos. All the animals were maintained on commercial animal feed (growers mash) throughout the period of the

experiment which lasted for 28 days. After 28 days exposure, blood was collected from the animals by ocular bleeding and delivered into clean and labeled test-tubes. The blood was allowed to clot and serum was separated by centrifugation at 3000 rpm for ten minutes, transferred into a clean, dry bottle and stored in a freezer for the determination of testosterone, protein and cholesterol concentration.

Enzyme immunoassay of serum testosterone was determined according to the method of Tietz (1999). The analysis was carried out using a commercially available analytical kit (Biocheck Foster City). The absorbance was read at 450nm with a microtitre well reader within 15 minutes and concentration determined from an already prepared standard curve.

The animals were sacrificed by cervical dislocation and dissected to remove the epididymis. The left cauda epididymis was excised and used for sperm counting by the method of Amann and Almquist (1961). The left cauda epididymis was blended with mortar and pestle, homogenized in 5ml of 9% normal saline for about 2 minutes, until a homogenate mixture was obtained. The homogenate (0.1ml) was transferred into another test-tube and diluted with 0.9ml of white blood cell (WBC) diluting fluid. The mixture was fed into the neuber chamber (haemocytometer) and with a microscope with x10 magnification. The testes of the dissected animals were also excised and adherent tissues removed. The wet weight of both testes was taken directly using analytical balance. Then, the average weight of the testes was recorded as the testicular weight.

Cholesterol was estimated by the modified method of Rulel and Morris (1976). An aliquot from the chloroform extract was dried under a stream of nitrogen followed by the addition of 1.5ml of ferric chloride – acetic acid reagent. After mixing thoroughly, it was left at room temperature for 15 minutes. Concentrated sulfuric acid (1ml) was added, mixed immediately on a vortex mixer and left at room temperature in the dark for 45mins the intensity of the clear solution was measured in the spectrophotometer at 450nm. The cholesterol level in biological sample was estimated from the standard curve generated with Analar cholesterol (30 – 150ng).

Serum total protein was estimated by Biuret method as described by Gonall et al (1949).

Histological examination of the testis was carried out using a slight modification of the method described by Okoro (2002). The tissues were fixed on glass slides by allowing them to pass through ascending grades of alcohol (30%, 50%, 70%, 90% and absolute alcohol) for 1hr, 2hrs and 3hrs each.

After dehydration, the alcohol was removed from the tissue by immersing them in xylene for 3 hours. The tissues were then impregnated by transferring them to a bath of molten paraffin wax in the embedding oven. After the impregnation, they were stained by immersing in Harris Haematoxylin for 30 minutes, washed thoroughly in running tap water and counterstained with eosin for 1 minute. They were finally dehydrated in ascending grades of alcohol, cleared in xylene and mounted with DPX (Dibutylphthalate, polystyrene, xylene).

Data Collected were analyzed using one – way ANOVA and subjected to LSD test for multiple comparisons using the program statistical package for social sciences (SPSS) version 17. Results were expressed as mean I SEM and difference between means of treated and control group accepted significant at ($p < 0.05$).

3. Results

There was significant reduction ($p < 0.05$) in the level of testosterone in the rats exposed to dichlorvos compared to the control. The lowest testosterone (3.3 mmol/L) was recorded in the group exposed to 0.01% dichlorvos (Table 1). There was also a significant reduction in sperm counts of rats exposed to dichlorvos. The sperm counts reduced with increase in pesticide concentration with lowest sperm count of $4.35 \pm 1.9 \times 10^6$ recorded in the rats exposed to 0.05% pesticide (Table 1).

Table 1: Effect of dichlorvos on the testosterone and sperm count of male albino rats

Treatments	Testosterone level (mmol/L)	Sperm count ($\times 10^6$)
Control	$35.10^a \pm 0.05$	$11.50^a \pm 1.8$
0.01% DDVP	$3.3^b \pm 0.06$	$8.50^b \pm 1.5$
0.03% DDVP	$3.35^b \pm 0.03$	$7.25^c \pm 2.6$
0.05% DDVP	$6.72^c \pm 0.01$	$4.35^d \pm 1.9$

Values expressed as standard error values \pm of the samples (N=3). ^{a-d}Means within a column with no common superscript differ significantly at $p < 0.05$

There were significant reductions ($p < 0.05$) in the weights of the testis and epididymis of rats exposed to dichlorvos. The weight of testis reduced from 2.128 ± 0.079 g in the control to 1.116 ± 0.271 g in the rats exposed to 0.05% dichlorvos (Table 2). The lowest weight of epididymis (0.25 ± 0.03 g) was recorded in the rats exposed to 0.01% dichlorvos as against the control (0.52 ± 0.25 g).

There was a significant increase ($p < 0.05$) in serum total protein of rats exposed to dichlorvos. The highest protein concentration of 55.92 ± 1.3 g/L was recorded in the rats exposed to 0.03% dichlorvos. However, this was not the case with the serum

cholesterol. The total cholesterol increased from 69.27 ± 11.81 mg/dL in the control to 74.93 ± 9.91 mg/dL in the rats exposed to 0.01% dichlorvos, then reduced to 66.30 ± 3.81 mg/dL in the rats exposed to 0.03 and 0.05% dichlorvos, respectively. The total serum protein and cholesterol are shown in table 3.

Table 2: Effect of dichlorvos on weights of testis and epididymis of male albino rats

Treatment	Weight of testis (g)	Weight of epididymis (g)
Control	$2.128^a \pm 0.079$	$0.52^a \pm 0.025$
0.01% DDVP	$1.722^b \pm 0.034$	$0.25^b \pm 0.03$
0.03% DDVP	$1.840^b \pm 0.045$	$0.35^c \pm 0.01$
0.05% DDVP	$1.116^c \pm 0.027$	$0.34^c \pm 0.05$

Values expressed as standard error values \pm of the samples (N=3). ^{a-c}Means within a column with no common superscript differ significantly at $p < 0.05$

Table 3: Total serum protein and cholesterol concentration of male albino rats exposed to dichlorvos

Treatment	Total protein (g/L) (Mean \pm S.E.M)	Total cholesterol (mg/dL) (Mean \pm S.E.M)
Control	$41.66^a \pm 0.69$	$69.27^a \pm 11.81$
0.01% DDVP	$47.34^b \pm 7.07$	$74.93^b \pm 9.91$
0.03% DDVP	$55.92^c \pm 1.3$	$66.30^c \pm 3.81$
0.05% DDVP	$45.58^d \pm 2.6$	$66.30^c \pm 3.81$

Values expressed as standard error values \pm of the samples (N=3). ^{a-d}Means within a column with no common superscript differ significantly at $p < 0.05$

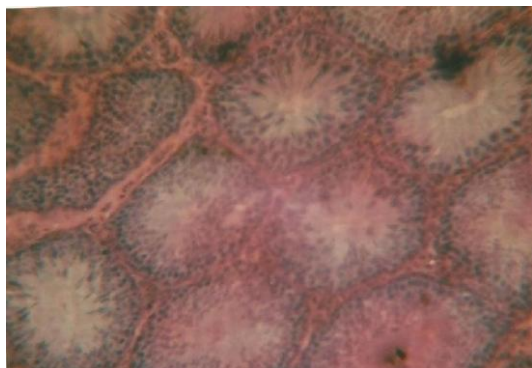


Fig. 5a: Testicular section of control rat

Results of histological examination of the testis of rats in the control group as well as those exposed to different concentrations of dichlorvos revealed a number of differences in the structure of the cells. A photomicrograph of the control testis using X400 magnification shows numerous seminiferous tubules. In between the tubules are interstitial cells of leydig embedded within the connective tissues. Within the lumen of the seminiferous tubules are outlined

different spermatogenic cells intercalated with the sustentacular cells. The lumen is also filled with spermatozoa seen as tiny threadlike substances (Fig.5a).

Figure 5b shows photomicrograph of testis in rats exposed to 0.01% dichlorvos. There were slight cellular distortions in the seminiferous tubules compared to the control.

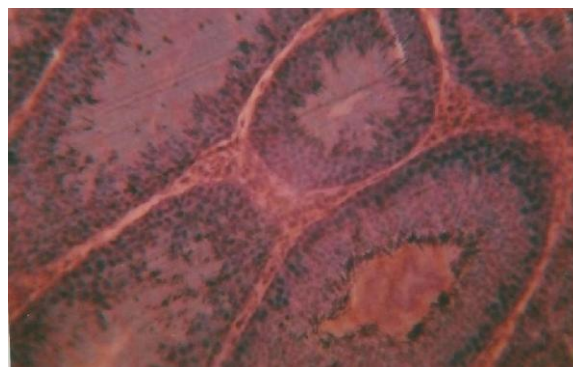


Fig. 5b: Testicular section of rat exposed to 0.01% dichlorvos

In the testis of the rats exposed to 0.03% dichlorvos (Fig.5c), it was observed that there was hypertrophy of the spermatogonia cells. The tissues were thick and there were reduction in the spermatozoa as no sperm cells were found in the lumen of the seminiferous tubule.

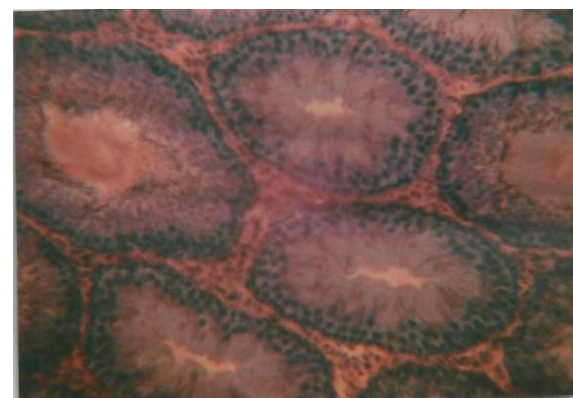


Fig. 5c: Testicular section of rat exposed to 0.03 % dichlorvos

A similar thing was also observed in the group exposed to 0.05% dichlorvos (Fig. 5d). There were also hypertrophy of the spermatogonia cells and subsequent reduction in sperm production as the lumen appeared empty.

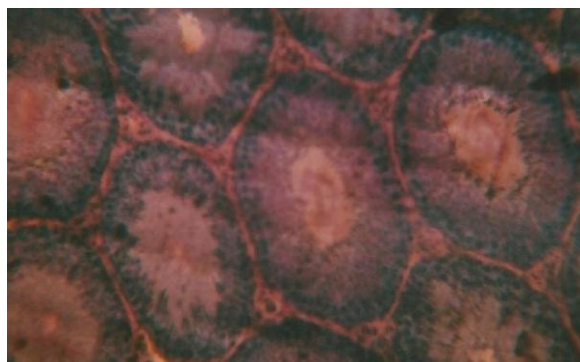


Fig. 5d: Testicular section of rat exposed to 0.05 % dichlorvos

4. Discussions

Organophosphates are among the most widely used synthetic insecticides (Pedigo, 1991). The widespread use of organophosphates has stimulated research into the possibility of affecting the reproductive activities of humans and animals exposed to them (Suresh et al., 2007). Assessment of the reproductive toxicity of organophosphorous insecticides is therefore an important public health issue. Dichlorvos, a typical organophosphate insecticide, has wide applications in both agriculture and domestic use.

Results of this study show significant reduction in the level of testosterone in rats exposed to dichlorvos. Testosterone is a very important hormone produced in the testes of males which plays a crucial role in male reproductive functions. Significant alterations in testosterone have been reported in animals exposed to some organophosphate insecticides. Mansour et al. (2008) and Uzon et al. (2009) reported a reduction in testosterone in rats treated with malathion. Exposure to methyl parathion has also been reported to significantly reduce testosterone levels (Maitra and Mitra, 2008). These reports suggest that pesticides have negative effect on sex hormone especially testosterone which plays an important role in spermatogenesis (Kamijima et al., 2004).

There were significant reductions in the testicular weight of rats exposed to dichlorvos compared to the control. The weight of the testis is one of the markers of possible alteration in androgen status (Latif et al., 2008). A number of reasons have been suggested for the reduction in testicular weight of animals exposed to pesticides. The reduction in the weight of the testis may be as a result of degeneration of the seminiferous tubules. Chitra et al. (1999) suggested that the decline in weight of the testis may be due to impairment of testicular, pituitary, or hypothalamic glands. Simanainen et al. (2008) attributed the decrease in testicular weight of rats

exposed to dichlorvos to decreased level of serum testosterone because androgen exerts its major role in sex organs. Okamura et al. (2005) however observed no significant difference in testicular weights between rats exposed to dichlorvos and that of the control. Our report also shows a reduction in the weight of the epididymis in rats exposed to dichlorvos.

Sperm count reduced significantly ($p < 0.05$) in the rats exposed to dichlorvos. The reduction in sperm count may not be unconnected to the reduction in testosterone which plays an important role in spermatogenesis. Chaudhary and Joshi (2003) attributed the low sperm count to the impairment of testicular functions which affected the activities of the enzymes responsible for spermatogenesis. Other organophosphate pesticides reported to reduce sperm count include malathion (Contreras and Bustos-Obregon, 1999) and Chlorpyrifos (Joshi et al., 2007).

There was a significant increase ($p < 0.05$) in serum total protein of rats exposed to dichlorvos. Otijolu and Onwurah (2006), however reported a reduction in plasma protein in rats exposed to a pyrethroid (Rambo Insecticide). The effect of dichlorvos on serum cholesterol was not consistent. The cholesterol level increased with pesticide exposure but later reduced.

Histological examination of the testes revealed various degrees of cellular degeneration in rats exposed to dichlorvos. The effects became more severe with increase in concentration of dichlorvos. Photomicrograph of the testes of rats exposed to 0.03 and 0.05% dichlorvos showed that there was hypertrophy of the spermatogonia cells which eventually led to a reduction in sperm production. Krause et al. (1976) reported slight reduction in spermatogenic cells and Leydig cells in juvenile rats treated with dichlorvos and malathion.

Acknowledgements:

The authors are grateful to the staff and management of Silverpresh Research laboratory Owerri for their technical support towards this project.

Corresponding Author:

Dr. Ethelbert Uchechukwu Ezeji
Department of Biotechnology Federal
University of Technology P.M.B
1526, Owerri, 460001 Nigeria E-
mail: uchezeji@yahoo.com

References

1. Bloomquist JR. Neuroreceptor mechanism in pyrethroid mode of action and resistance, *Rev. Pestic. Toxicol.* 1993; (2): 185-226.
2. De Bleecker J, Van den Neucker K, Colardyn F Intermediate syndrome in organophosphorus poisoning: a perspective study, *Crit Care Med.* 1993; (21): 1706-1711.
3. Eskenazi, B., Bradman, A., Castrina, R Exposure of children to organophosphate pesticides and their potential adverse health effects. *Environmental Health Perspective*, 1993; 107(3): 409-419.
4. World Health Organization. The WHO recommended classification of pesticides by hazard and guide lines to classification 1992 - 1993 (WHO / PSC / 92.14). 1992; Available from the international programme on chemical safety, World Health Organization, Geneva, Switzerland.
5. Taylor JS, Thomson BM, Lang CN, Sin FY, Podivinsky E. Estrogenic pyrethroid pesticides regulate expression of estrogen receptor transcripts in mouse sertoli cells differentially for 17 beta-estradiol. *J Toxicol Environ Health*, 2010; 73(16): 1075-1089.
6. Collata M Epigenetics and Pesticides. *Toxicology*, 2013, (307): 35-41
7. Bretveld R, Brouwers M, Ebisch I, Roeleveld N. Influence of pesticides on male fertility. *Scand J Work Environ Health*, 2007, 33(1): 13-28.
8. Tietz C. Economic Impact of Reduced Pesticide Use in the United State. Agricultural and Food Policy Center, Texas A and M University, 1999.
9. Amann RP, Almquist JO. Reproductive capacity of dairy bulls 1. Techniques for direct measurement of testicular sperm production. *Journal of Dairy Science*, 1961, 45: 774-775.
10. Rudel L, Morris M. determination of cholesterol using O-phthaldehyde, *J. Lipid Res.* 1976, 14(1973): 354.
11. Gornall AG, Bardawill CS, David MM. Determination of serum proteins by means of Biuret reaction. *Journal of Biology and Chemistry*, 1949, (177): 751-766.
12. Okoro I. *Manual of Practical Histology*, 2002, Second Edition Peace Publishers, Owerri.
13. Pedigo LP. *Entomology and Pest Management*. MacMillan Publishing Company, New York. 1991, Pp. 360.
14. Suresh C, Joshi R, Mathur PP, Gulati N. Testicular toxicity of chlorpyrifos (an organophosphate pesticide) in albino rats. *Toxicology Industrial Health*. 2007, 23: 439.
15. Mansour, S.A, Mossa, A.H., Heikai, T.M. Cytogenetic and Hormonal alteration in rats exposed to recommended "Safe Doses" of Spinosaf and malathion insecticides. *International Journal of Agriculture and Biology*, 2008, 10(1): 9-14
16. Uzon FG, Kalender S, Durak D, Demir F, Kalender Y. Malathion-induced testicular toxicity in male rats and the protective effect of vitamins C and E. *Food and Chemical Toxicology*, 2009,(47): 1903 –1908.
17. Maitra SK, Mitra A. Testicular functions and serum titers of LH and testosterone in methyl parathion-fed resoringed parakeets. *Ecotoxicol. Environ. Saf.*, 2008, (71): 236–244.
18. Kamijima M, Hibi H, Gotoh M, Taki K, Saito I, Wang H. A survey of semen indices in insecticide sprayers. *Journal of Occupational Health.*, 2004, (46): 109-118.
19. Latif R, Lodhi GM, Aslam M. Effects of Amlodipine on Serum Testosterone, Testicular Weight And Gonado-Somatic Index In Adult Rats. *J Ayub Med Coll Abbottabad*, 2008, 20(4): 8-10.
20. Chitra KC, Latchoumycandane C, Mathur PP. Chronic effect of endosulfan on the testicular functions of rat. *Asian J. Andrology*, 1999, (1): 203-206.
21. Simanainem U, McNamara K, Davey RA, Zajae JD, Handelsman DJ. Severe subfertility in mice with androgen reporter inactivation in sex accessory organs but not in testis. *Endocrinology*, 2008, 49: 3330-3338.
22. O, Kamijima M, Shibata E, Ohtani K, Takagi K, Ueyama J, Watanabe Y, Omura M, Wang H, Ichihara G, Kondo T, Nakajima T. A comprehensive evaluation of the testicular toxicity of dichlorvos in Wistar rats. *Toxicology*. 2005, 213(1-2):129-137.
23. Choudhary N, Joshi SC. Reproductive toxicity of Endosulfan in Male Albino Rats, *Bull. Environ. Contami. Toxicol.* 2003, (70): 285-289.
24. ContrerasHR, Bustos-Obregon E. Morphological alterations in mouse testis by a single dose of malathion. *Journal of Experimental Biology*, 1999, 284(3): 355-359.
25. Joshi SC, Mathur R, Gulati N. Testicular toxicity of chloropyrifos (an organophosphate pesticide) in albino rats. *Toxicology and Industrial Health*, 2007, (23): 439-444.
26. Krause W, Hamm, K, Weissmulter J. The effect of per orally administered DDVP and malathion on spermatogenesis and leydig cell in the juvenile rat. *Andrology* 1975, 7(2): 109-116.
27. Otijolu O, Onwurah INE. Glutathione S-transferase (GST) Activity as a Biomarker in Ecological Risk Assessment of Pesticide Contaminated Environment. *African Journal of Biotechnology*, 2007, 6(12): 1455-1459.