

DIABETES MELLITUS AND SOME OF ITS EFFECT ON THE EYES AMONG ADULTS OF RURAL COMMUNITIES AT OHAFIA L.G.A OF ABIA STATE NIGERIA

*AZUAMAH Y.C.

Department of Optometry
Madonna University Elele Campus Rivers State, Nigeria
Email: youngazuamah@yahoo.com
+2348034933590

AMADI A.N.

Department of Public Health Technology
Federal University of Technology Owerri, Imo State, Nigeria
Email: amadian2003@yahoo.com
+2348037061795

AMADI C.O.A.

Department of Public Health Technology
Federal University of Technology Owerri, Imo State, Nigeria
Email: ecotechnigeria@yahoo.com
+2348039598111

ABSTRACT

This study was carried out on adults at Ohafia Local Government of Abia State in Nigeria to determine the presence of ocular effects that resulted from diabetes mellitus. This study was a field based study in which subjects were made to assemble at a health center and the examinations and tests carried out. Out of the 213 subjects examined and tested, 48 of them (27 males and 21 females) were found to have a history of diabetes mellitus. The presence of ocular effects of diabetes on these subjects showed that 31.25% of the subjects (33.3% of the males and 28.6% of the females) had diabetic cataract. Diabetic retinopathy was found on 6.25% of the subjects (0% of the males and 14.3% of the females). Also 6.25% of the subjects showed diabetic macular edema, 0% were males and 14.3% were females. Diabetic papillopathy was found in 31.25% of the subjects out of which 22.2% were males and 42.8% were females. 37.5% of the diabetic subjects were found to have glaucoma, 22.2% of them were males and 57.1% of them were females. One or a combination of these ocular effects of diabetes was seen on some subjects. Data analysis with the SPSS statistics software using the T test showed that there was no significant difference between the male and female subjects to the ocular effects of diabetes mellitus.

KEYWORDS: *Diabetic mellitus, cataract, retinopathy, macular edema, glaucoma.*

INTRODUCTION

Diabetes Mellitus is a disorder caused by insufficient or absent production of the hormone insulin by the pancreas, or because the tissues are resistant to the effects. Insulin is responsible for the absorption of glucose into cells. Lack of insulin causes high blood levels of glucose. Blood glucose values are normally maintained in a very narrow range, usually 70 to 120mg/dl.

Some of the ocular effects of diabetes include diabetic retinopathy, diabetic macular edema, diabetic papillopathy and diabetic cataract. Glaucoma is also associated with diabetes mellitus.

Diabetic cataract is as a result of osmotic over hydration of the lens. With a pen light or slit lamp examination, the appearance of the lens is white and opaque¹.

Diabetic retinopathy usually manifests in the later stages of diabetes mellitus. Upon ophthalmoscopy, there are small, bright, white or yellow spots seen in and around the macular region. There are also presence of cotton wool spots, dot hemorrhages, microaneurysms and exudates on the retina².

Diabetic macular edema presents as hard exudates on the center of the fovea. There is leaking of fluid from blood vessels within the macula which causes swelling of the retina³.

Diabetic Papillopathy presents with optic disc edema. Ophthalmoscopic examination shows the presence of disc swelling, blurring of the disc margins and venous engorgement⁴.

Glaucoma is a condition that is characterized by an increase in the intraocular pressure of the eye leading to the loss of blood supply to the optic nerve resulting in death of the optic nerve and then blindness.

A case report study was carried out on a 41 year old female to determine the refractive changes in a newly diagnosed diabetic at the University of Benin, Nigeria. After 5 months of follow up, it was found that there were refractive changes with the fluctuations of blood glucose levels⁵. In a study to measure the prevalence of diabetes mellitus in a traditional Yoruba community in the city of Ibadan, Nigeria; the findings of the study showed that the prevalence of Type 2 diabetes seems to be in the increase⁶. In a study to determine the Oculo Visual problems in Alayi community of Abia State, Nigeria; 587 subjects between the age of 18 and 73 were studied. From the results, 192 (32.71%) subjects had cataract, 97 (16.52%) had allergic

conjunctivitis, 72 (12.2%) had glaucoma. Other visual problems found were refractive errors, age related macular degeneration, presbyopia and corneal opacities⁷. A study to assess the prevalence rates of type 2 diabetes and to determine the potential associated risk factors of the disease in Port-Harcourt, Nigeria was done using 502 subjects above 40 years. From the results, 34 subjects had diabetes giving a prevalence rate of 6.8%; 7.7% for males and 5.7% for females. It concluded that the prevalence of type 2 diabetes in Port-Harcourt is relatively high⁸. This was related to the changing lifestyle associated with industrialization. In a study to access the prevalence of diabetes mellitus in Dakace village near Zaria, Nigeria; 199 subjects (94 males and 105 females) had their fasting blood glucose and body mass indices determined. The overall prevalence of diabetes was 2.0%. It was concluded that the prevalence of diabetes mellitus in the semi urban community is growing as with other parts of Nigeria⁹. The visual acuity of people living with diabetes has a tendency to reduce following these ocular manifestations. The prevalence of self-rated visual impairment was 24.8% in a study to estimate the prevalence of self-rated visual impairment among US adults with diabetes mellitus¹⁰. A case-control study to screen for impaired distance visual acuity in older adults living in three districts of Wales to determine whether diabetes mellitus increases the likelihood of visual impairment showed that impairment in visual acuity was observed in 40% of those with diabetes mellitus and 31% of the control (Sinclair et al 2000). They concluded that diabetes mellitus was associated with significantly increased risk of visual loss. In US, the Center for Disease Control (CDC) analyzed 1999-2004 data from the National Health and Nutrition Examination Survey (NHANES). Report of the analysis indicated that among US adults aged 20 years and above with diabetes, 11% had visual impairment¹¹.

MATERIALS AND METHODS

Ohafia Local Government Area with its headquarters at Ebem was created in June 1989, from the old Arochukwu/Ohafia Local Government Area. It is located in Abia state, in the southeast geographical area of Nigeria. Ohafia L.G.A shares borders with Arochukwu L.G.A in the south, Bende L.G.A in the west, Afikpo South L.G.A of Ebonyi State in the north and Biase L.G.A of Cross River State in the east. They are matrilineal Igbo speaking people with a rich cultural heritage. Cultural festivals include the new yam festival, *igba ekpe*, and the *egwu onwa* music¹². There are 27 autonomous communities each headed by a traditional ruler. Ohafia people are traditionally farmers. One can also find people engaged in other professions like traders, civil servants and transport workers.

A total of 213 subjects assembled at a health center at Okagwe Ohafia for this study. The ages of these subjects were from 18 years and above. Over 70% of the subjects were over 50 years of age. A complete case history was taken on each subject. Those who have a history of diabetes mellitus were noted. The subjects' eyes were carefully examined with a pen touch to determine the presence of any external ocular disease. The ophthalmoscope was then used to examine the internal media. The presence of any signs that would indicate pathology was noted. The blood glucose levels of the subjects were measured and recorded.

RESULTS

Out of the 213 subjects examined, 48 subjects were found to have a history of diabetes, 27 of them were males and 21 were females. Table 1 shows the frequency distribution of ocular effects of diabetes of the male and female subjects. 9 out of the 27 male subjects had diabetic cataract making up 33.3% of the male subjects with diabetes while 6 of the 21 female subjects had diabetic cataract making up 28.6% of the females with diabetic cataract. None of the male

subjects presented with diabetic retinopathy and none of the male subjects also presented with diabetic macular edema. On the other hand, 3 female subjects presented with diabetic retinopathy making up 14.3% of the female subjects with diabetes. Also 3 female subjects presented with diabetic macular edema. This also represented 14.3% of the female subjects with diabetes. 6 of the male subjects presented with diabetic papillopathy representing 22.2% of the males with diabetes and also 6 presented with glaucoma representing 22.2% of the males with diabetes. 9 female subjects showed the presence of diabetic papillopathy and 12 female subjects had glaucoma. This represented 42.8% and 57.1% respectively of the subjects with diabetes mellitus.

Table 1: Frequency distribution of ocular effects of diabetes mellitus among subjects at Ohafia L.G.A

OCULAR DISEASE	Absolute frequency	Percentage frequency (%)
Diabetic Cataract	15	31.25
Diabetic Retinopathy	3	6.25
Diabetic Macular edema	3	6.25
Diabetic Papillopathy	15	31.25
Glaucoma	18	37.5

Table 2: Frequency distribution of ocular effects of diabetes mellitus among male and female subjects at Ohafia L.G.A

OCULAR DISEASE	MALES		FEMALES	
	Absolute frequency	Percentage frequency (%)	Absolute frequency	Percentage frequency (%)
Diabetic Cataract	9	33.3	6	28.6
Diabetic Retinopathy	0	0	3	14.3
Diabetic macular edema	0	0	3	14.3
Diabetic Papillopathy	6	22.2	9	42.8
Glaucoma	6	22.2	12	57.1

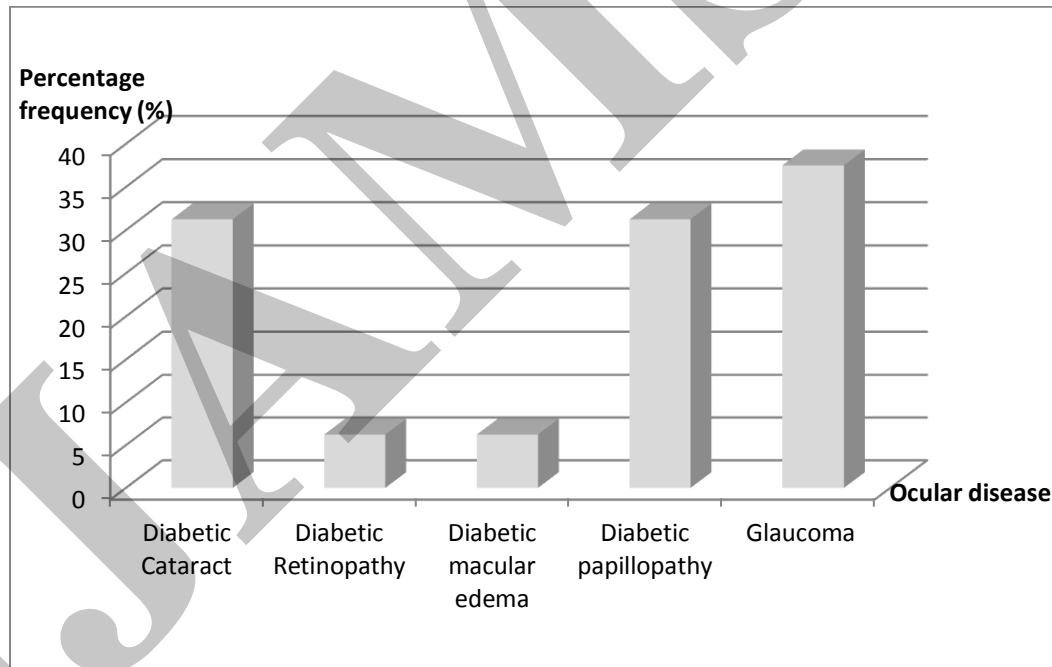


Fig 1: Percentage frequency ocular effects of diabetes mellitus among subjects at Ohafia L.G.A

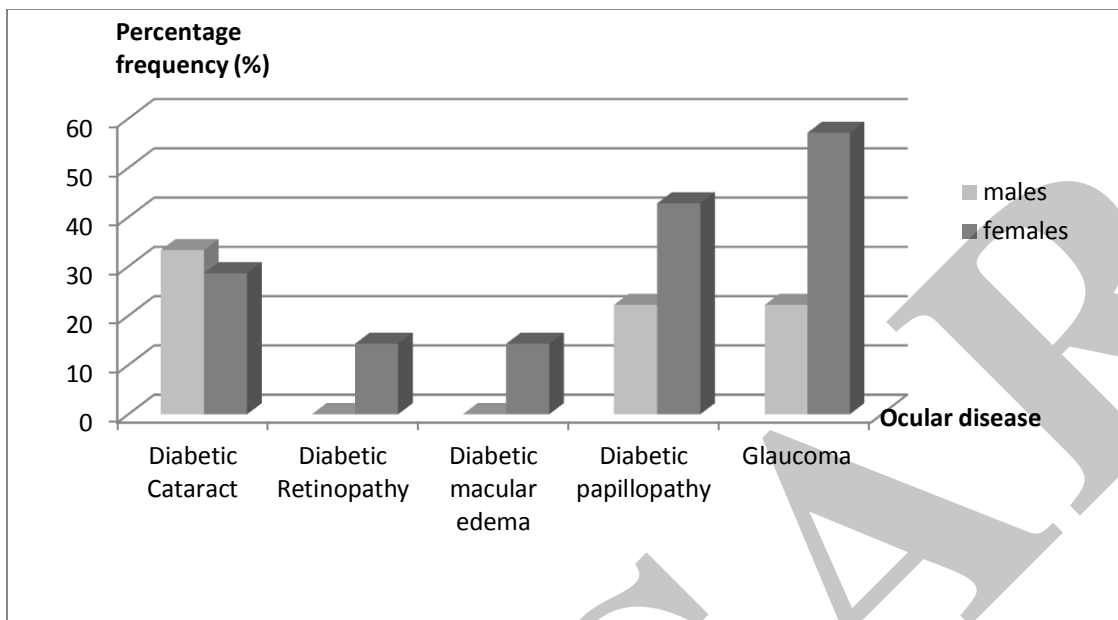


Fig 2: Percentage frequency of ocular effects of diabetes mellitus among male and female subjects at Ohafia L.G.A

DISCUSSION

The major ocular effects of diabetes mellitus in the eyes include diabetic cataract, diabetic retinopathy, diabetic macular edema, and diabetic papillopathy. These ocular diseases can lead to total blindness. Glaucoma is also known to be associated with the presence of diabetes mellitus. From this study, 213 subjects were examined and 48 were found to have type 2 diabetes. Table 1 shows the general frequency distribution for all the subjects while Table 2 shows the frequency distribution of the ocular disorders for the male and female subjects. The presence of diabetic cataract was found in 15 of these subjects making up 31.25%. 9 of the subjects were males (33.3%) and 6 subjects were females (28.6%). Diabetic retinopathy which is known to manifest in the advanced stages of diabetes was not seen in any of the male subjects but was found in three female subjects. The same also goes for diabetic macular edema which manifests in relation to diabetic retinopathy. In a cohort study to quantify the prevalence of diabetic

retinopathy and cataracts in patients with type 2 diabetes in 3 centers in Lagos, Enugu and Ibadan, Nigeria, a prevalence of 44.9% and 17.9% was found for diabetic cataract and diabetic retinopathy respectively¹³. A study in Pakistan also found a low prevalence (0.6%) of subjects with diabetic retinopathy¹⁴. In this study, diabetic papillopathy was found in 15 subjects, 6 male subjects and 9 female subjects. They made up 31.25% of the diabetic subjects. Glaucoma showed the highest frequency with 18 subjects (37.5%) having the disease, out of which 6 (22.2%) were males and 12 (57.1%) were females. In a study in Lagos state Nigeria to determine the common ocular manifestations of cerebrovascular accidents in hypertensive and diabetic patients, results showed glaucomatic changes in 30% of the 80 patients examined¹⁵. The percentage distribution of the male and female subjects is shown in figure 2. The figure shows a greater percentage frequency among the female subjects than the male subjects except for diabetic cataract. Figure 1 shows that glaucoma, diabetic cataract and diabetic papillopathy has the greatest percentage frequency of the ocular disorders as a result of diabetes mellitus. In a study at the Diabetic eye clinic, Nnamdi Azikiwe University teaching hospital Nnewi Nigeria, glaucoma, cataract, diabetic retinopathy and central retinal vein occlusion was found to be the major causes of low vision in Nigerians with diabetes¹⁶. The ocular manifestations in this study appeared alone in some cases while in others there was a combination of effects. Some appear in relation to others. For instance, diabetic macular edema usually presents its ophthalmoscopic signs in the presence of diabetic retinopathy, thus subjects with signs of diabetic retinopathy also showed signs of diabetic macular edema and vice versa. Also swelling of the optic nerve head which is seen of diabetic papillopathy is also seen in glaucoma. Some of the subjects showed a combination of these ocular effects.



Fig 3: Subjects waiting to be examined at a health center at Ohafia L.G.A.

Analysis with the SPSS statistics software using the T test to test the relationship between the male and female subjects of these ocular diseases, the P value from the SPSS data output was 0.945 and this was higher than the 0.05 level of significance. This result means that there is no significant difference in the ocular effects of diabetes between the male and female subjects at Ohafia L.G.A., Nigeria.

These ocular effects resulted in the significant reduction in the visual acuity of these people. As a result of this, many of them can no longer perform their tasks adequately. Many had to retire from their jobs as they could no longer do their job effectively. Those engaged in commercial driving are among those hardly hit because without their sight, there is no chance of them doing their job. Also those in other jobs like farming, trading, and sewing complained bitterly of inability to do their jobs. These people could no longer earn a living and had to be dependent on family members to be able live their lives. Those whose sight has been lost completely in both eyes became completely dependent and a burden on others. With lack of adequate health care and health professionals, the people of these communities have to travel far to the cities in search

of adequate health care. Most of them who do not have the means to travel or who cannot afford it remain in their homes at the mercy of what help they can get from their relatives. Some have been abandoned by their families because they have become a source of burden to them. The effects of diabetes mellitus on the eyes has serious physical, psychological and socioeconomic consequences for the people and the communities and so adequate attention must be given to this problem in order to mitigate these effects.

REFERENCES

1. Kanski J. *Clinical Ophthalmology*, 3rd ed, Butterworth-Heinemann, 1998, 346-351.
2. Viswanath K., McGavin D.D. Diabetic Retinopathy: Clinical Findings and Management, *Community Eye Health*, 2003, 16:21-4.
3. Wilkinson C.P., Ferris F.L., Klein R.E. Proposed International Clinical Diabetic Retinopathy and Diabetic Macular Edema Disease Severity Scales, *Ophthalmology*, 2003, 110:1677-1682.
4. Tasman W., Jaeger E. *Atlas of Clinical Ophthalmology*, Lippincott-Raven, 1996, 281.
5. Osaiyuwu A.B., Emina M.O. The evaluation of children using monocular visual acuity and stereoacuity tests, *Journal of the Nigerian Optometric Association*, 2005, 12: 14-19.
6. Owoaje E., Rotimi C., Kaufman J., Tracy J., Cooper R. Prevalence of adult diabetes in Ibadan, *East African Medical Journal*, 1997, 74 (5): 299-302.
7. Ahuama, O.C. Oculo Visual Problems in Alayi Community of Abia State, Nigeria, *Journal of the Nigerian Optometric Association*, 2006, 13: 56-62.
8. Ebenezar A., Nyenwe A., Osaretin J., Odia A., Anele E., Ihekwa B., Ojule B., Babatunde B. Type 2 diabetes in adult Nigerians: A study of its prevalence and risk

- factors in Port Harcourt Nigeria, *Diabetes Research and Clinical Practice*, 2003, 62(23): 177-185.
9. Dahiru T., Jibo A., Hassan A., Mande A. Prevalence of diabetes in a semi-urban community in Northern Nigeria, *Nigerian Journal of Medicine*, 2008, 17(4): 14-16.
 10. Saaddine J.B., Narayan K.M., Engelgau M.M., Aubert R.E., Klein R., Beckles G.L. Prevalence of Self-Rated Visual Impairment among Adults with Diabetes, *American Journal of Public Health*, 1999, 88(8): 1200-1205.
 11. Zhang X., Gregg E.W., Cheng Y.J. et al. Correctable Visual Impairment among Persons with Diabetes, *Center for Disease Control and Prevention, MMWR Weekly*, 2006, 55(43): 1169-1172.
 12. Ohafia Local Government Area. It's Rich Cultural Heritage, *Ohafia Forum*, 2010, 6(2):28.
 13. Rotimi C., Daniel H., Zhou J. et al. Prevalence and determinants of diabetic retinopathy and cataracts in West African type 2 diabetes patients, *Ethnicity and Disease*, 2003, 13(2):110-117.
 14. Shaikh A., Shaikh F., Shaikh Z.A., Ahmed J. Prevalence of Diabetic Retinopathy and Influence Factors among Newly Diagnosed Diabetics in Rural and Urban areas of Pakistan: Data Analysis from the Pakistan National Blindness and Visual Impairment Survey 2003, *Pakistan Journal of Medical Sciences*, 2008, 24(6): 405-411.
 15. Asonye, C., Chukwulobe, M., Oveneri-Ogbomo, G., Akpalaba, R. The common ocular manifestations of cerebrovascular accidents in hypertensive and diabetic patients A case study of Lagos state Nigeria, *The Optometric Educator*, 2009, 4(1):31-34.
 16. Sabastian N., Nwosu N. Low vision in Nigerians with diabetes mellitus, *Documenta*

Ophthalmologica, 2009, 101(1):51-57.

17. Backlund L.B., Algvare P.V., Rosenqvist U. New Blindness in Diabetes reduced by more than one-third in Stockholm County, *Diabetic Medicine*, 1997, 14:732-40.
18. Dandona L., Dandona R., Naduvilath T.J., Mccarty C.A., Rao G.N. Population based assessment of Diabetic Retinopathy in an urban population in Southern India. *Br J Ophthalmol*, 1999, 83:93.
19. Eisenbarth G. Type 1 Diabetes: A Chronic Autoimmune Disease, *New England Medical Journal*, 1986, 314:1360.
20. Ekoe J, Zimmet P, Williams R. The Epidemiology of Diabetes Mellitus: An International Prospective, *An International Journal of Epidemiology*, 2002, 31:878.
21. Frank R.N. Diabetic Retinopathy, *N Engl J Med*, 2004, 350:48-58.
22. Javadi M.A., Katibeh M., Rafati N., et al. Prevalence of Diabetic Retinopathy in Tehran Province, A Population-Based Study, *BMC Ophthalmology*, 2009, 9(12): 1471-1479.
23. Jawad F. Diabetes in Pakistan, *Diabetic Voice*, 2003, 48(2):12-14.
24. Kumar, Abbas, Fausto. *Pathologic Basis of Disease*, 7th ed, Saunders Company, 2008, 1189-1206.
25. Sharma T., Sanjay S. The Impact of Diabetic Retinopathy on Health-Related Quality of Life, *Current Opinion in Ophthalmology*, 2005, 16(3): 155-159.
26. Shera A.S., Rafique G., Khawaja I.A. Pakistan National Diabetic Survey– Prevalence of Glucose intolerance & associated factors in different provinces of Pakistan, *J Pak Med Assoc*, 1999, 49:206-11.
27. Sinclair A.J., Bayer A.J., Girling A.J., Woodhouse K.W. Older Adults, Diabetes Mellitus and Visual Acuity: A Community Based Case-Control Study, *Pubmed*, 2000, 29(4): 335-

339.

28. Williams R., Airey M., Baxter H., Forrester J., Kennedy-Martin T. Epidemiology of Diabetic Retinopathy and Macular Edema: A Systematic Review, *Eye*, 2004, 18:963-983.
29. Wong T.Y., Loon S.C., Saw S.M. The Epidemiology of Age Related Eye diseases in Asia, *Br J Ophthalmol*, 2006, 90:506-11.
30. Young M. Many Visual Impairments among Persons with Diabetes, *Eye World News*, 2010, 27:16.
31. Zhang X., Gregg E.W., Cheng Y.J., et al. Diabetes Mellitus and Visual Impairment: National Health and Nutrition Examination Survey, 1999-2004, *Arch Ophthalmol*, 2008 126(10): 1421-1427.

COPYRIGHT AGREEMENT

Please complete and sign the form manually and send it with the final version of your manuscript. It is required to obtain **written confirmation** from authors in order to acquire copyrights for papers published in ISERP.

Title of paper: DIABETES MELLITUS AND SOME OF ITS EFFECT ON THE EYES AMONG ADULTS OF RURAL COMMUNITIES AT OHAFIA L.G.A OF ABIA STATE NIGERIA

Author(s): AZUAMAH Y.C., AMADI A.N., AMADI C.O.A.

The undersigned hereby transfer any and all rights in and to the paper including without limitation all copyrights to ISERP. The undersigned hereby represents and warrants that the paper is original and that he/she is the author of the paper, except for material that is clearly identified as to its original source, with permission notices from the copyright owners where required. The undersigned represents that he/she has the power and authority to make and execute this assignment. The undersigned hereby given permission to ISERP to publish the above contribution to the above Journal.

The Authors may not publish his/her contribution anywhere else without the prior written permission of the publisher unless it has been changed substantially. The copyright transfer covers the exclusive right to reproduce and distribute the contribution, including reprints, translations, photographic reproductions, microform, electronic form, or any other reproductions of similar nature. If the contribution is not accepted for publication, or if the contribution is subsequently rejected, this agreement shall be null and void. **Publication cannot proceed without a signed copy of this Agreement.**

This agreement is to be signed by at least one of the authors who have obtained the assent of the co-author(s) where applicable.


Author's Signature & Date (Manual Signature)

AZUAMAH YOUNG CHRISTIAN

Typed or Printed Name

MADONNA UNIVERSITY ELELE CAMPUS RIVERS STATE, NIGERIA.

Institution or Company



FirstBank
 Established 1894

FUNDS TRANSFER REQUEST FORM

BRANCH: OWERRI DATE: 7/10/2011

SWIFT TRANSFER DRAFT ISSUANCE

50k	ORDERING CUSTOMER NAME AND ADDRESS	Dr. Young Christian Azuamah Madonna University Eiele Nigeria
	DOMICILIARY ACCOUNT NUMBER	2018625561

33B	CURRENCY AND AMOUNT	\$ 200
	AMOUNT IN WORDS	Two hundred dollars

56	INTERMEDIARY BANK (NAME AND ADDRESS)	
	ACCOUNT NUMBER (BENEFICIARY BANK ACCOUNT WITH INTERMEDIARY BANK)	
	SWIFT CODE	
	ABA NUMBER/ ROUTING NUMBER/ SORT CODE /CHIP UID /BANK CODE (PLEASE SPECIFY)	

57	BENEFICIARY BANK (NAME, ADDRESS & BRANCH)	State bank of India (No. 15 R4E SUFFEREV Pondicherry India-605001)
	SWIFT CODE	SBININBB228
	ABA NUMBER/ ROUTING NUMBER/ SORT CODE / CHIP UID /BANK CODE (PLEASE SPECIFY)	

59	BENEFICIARY (NAME AND ADDRESS)	J. Amudhavel
	BENEFICIARY ACCOUNT NUMBER	20002756318

71A Details of Chargers BEN OURS SHA

70	REMITTANCE INFORMATION (PURPOSE)	manuscript publication fee form
----	----------------------------------	---------------------------------

72	SPECIAL INSTRUCTIONS (E.G. STUDENT NAME, ID NO., INVOICE NO., DATE OF BIRTH ETC)	
----	--	--

For my accounts, risk and subjected to the conditions overleaf, which I have read and understood, Please effect the transaction detailed above, and debit my/our above domiciliary account

CUSTOMER'S SIGNATURE (ACCORDING TO MANDATE) *[Signature]*

ACCOUNT OFFICERS NAME: *[Signature]* SIGNATURE *[Signature]*

BM/HBO'S NAME: _____ SIGNATURE _____

KINDLY ENSURE THAT DOMICILIARY ACCOUNTS ARE WELL FUNDED TO AVOID DELAYS IN TRANSFER REMITTANCES

The bank reserves the right to process a payment order presented with erasures and alterations.
 For any transfer outside Nigeria, with reference of foreign exchange approval(s). By the Signature here against the customer recognizes having read and understood the clauses and conditions of First Bank's funds transfer

IJMSAR